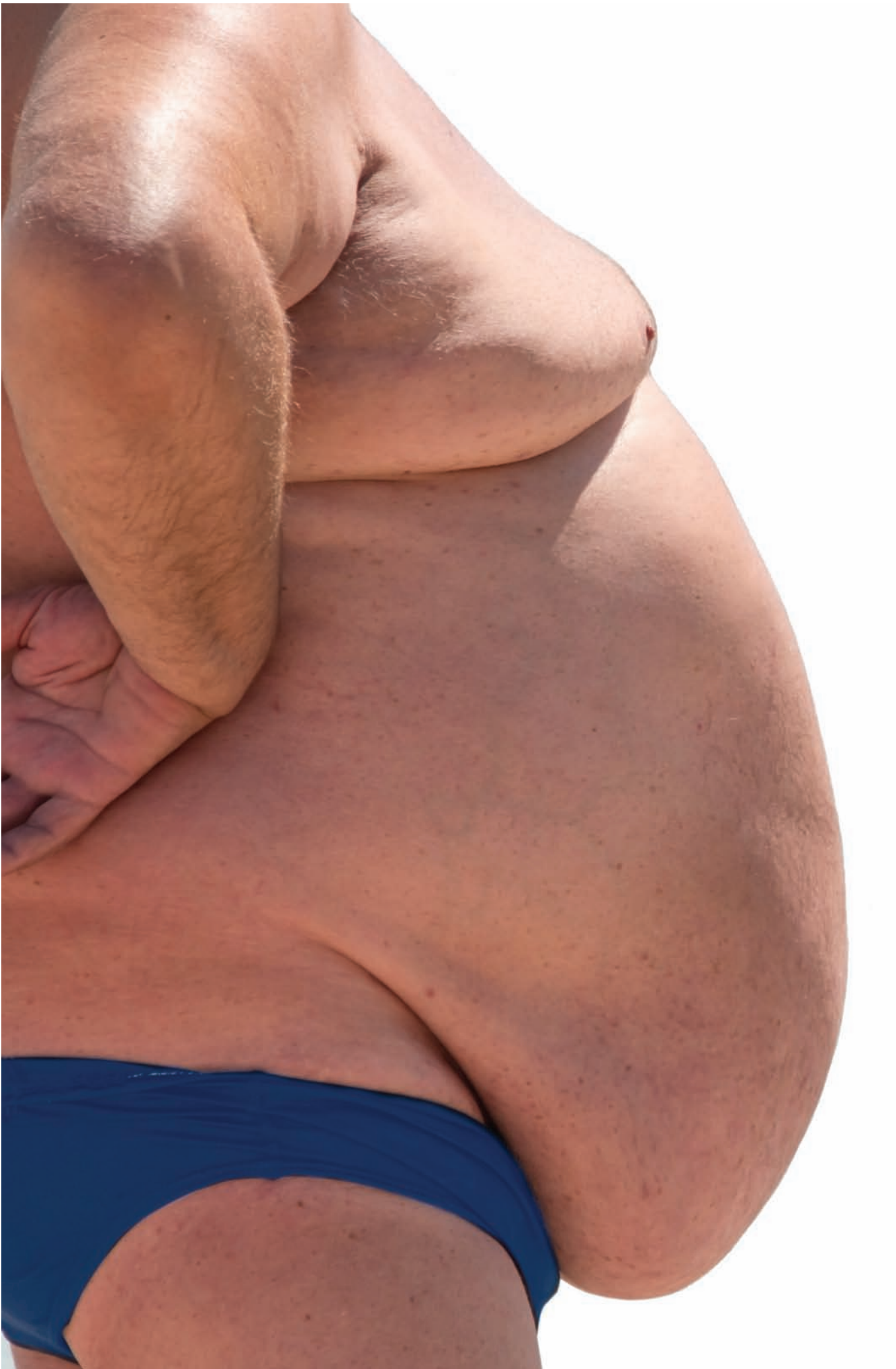



DENNISPRODUCTION.COM / SHUTTERSTOCK



1.0
ANCC CONTACT HOUR

Panniculectomy:

Perioperative nursing considerations

By Maurice Y. Nahabedian, MD, and
Anissa G. Nahabedian, BSN, RN

ALTHOUGH bariatric surgery is often successful in correcting obesity and type 2 diabetes mellitus, it can leave some patients with an excess of skin and fat.¹ This overhanging apron of tissue, called an *abdominal pannus*, may also cause health problems for obese patients. Besides diminishing quality of life, an abdominal pannus can cause maceration, infection, and poor hygiene.²

For some, correction is achieved by diet, exercise (focused on fat reduction), or strengthening (focused on core muscles). Other patients require surgery, such as abdominoplasty, panniculectomy, or liposuction. Keep in mind that many patients undergoing panniculectomy are or were overweight or obese.

This article reviews the management of patients undergoing panniculectomy. Surgical interventions are reviewed with an emphasis on nursing considerations, including preoperative, intraoperative, and postoperative factors.

Looking at anatomy

The anterior abdominal wall can be subdivided into three components: the skin and subcutaneous tissue, anterior and posterior rectus sheath, and muscle layers, including the paired rectus abdominis as well as the internal, external, and transverse oblique muscles.³ Abnormalities in abdominal contour may be the result of lipodystrophy, hernia, lack of muscle tone, prior surgery, or rectus abdominis diastasis (diastasis recti).⁴ (See *A closer look at the lower abdomen.*)

Panniculectomy is the excision of redundant skin and subcutaneous fat to improve the abdominal contour and alleviate many of the adverse effects of an overhanging pannus. In its simplest form, a panniculectomy involves removing excess skin and fat. In some patients, however, it can be performed in conjunction with the surgical correction of other abnormalities of the underlying anatomy, such as a hernia or diastasis recti.⁵

Panniculectomy often improves the patient's activities of daily living. Patients with an abdominal pannus may have other associated comorbidities such as obesity, diabetes mellitus, hypertension, chronic obstructive pulmonary disease, or hernia. Many patients have changes associated with the skin and soft tissue such as candidal intertrigo, dermatitis, and lymphedema that may

predispose the patient to infection and ulceration.⁶

Preoperative considerations

As with all elective surgeries, proper patient selection is important. A thorough history and physical examination are required and a careful assessment of the risks and benefits of panniculectomy must be determined. Many patients considering a panniculectomy have undergone bariatric procedures and have had massive weight loss. Weight fluctuations are common following bariatric surgery; however, weight should be stable for at least 3 months before panniculectomy.⁷

Any nutritional deficiencies should be addressed before surgery.⁷ Protein malnutrition and hypoalbuminemia are commonly seen in the postbariatric population. Other possible abnormalities include deficiencies

in iron as well as vitamin A, D, E, and K that, if not corrected, can increase blood loss and lead to poor wound healing.⁸

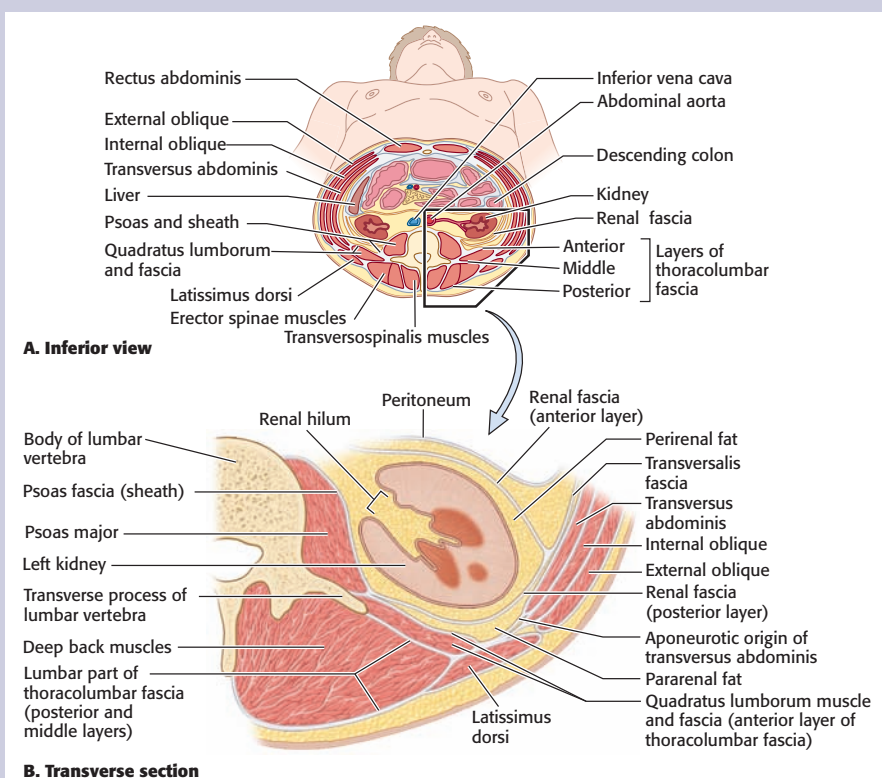
Patients must also be evaluated for prior abdominal hernia repair, prior abdominal surgeries, and comorbidities including diabetes mellitus, obesity, hypertension, pulmonary disease, poor nutritional status, cardiovascular disease, and connective tissue disorders. Patients with a body mass index (BMI) greater than 40, active tobacco use, uncontrolled diabetes mellitus, and poor nutritional status have an increased incidence of complications such as delayed healing, incisional dehiscence, soft-tissue necrosis, infection, hematoma, seroma, respiratory compromise, and venous thromboembolism (VTE).⁶ (See *How is BMI interpreted for adults?*)

In a study evaluating panniculectomy outcomes, 34% of patients had

A closer look at the lower abdomen

Fascia and aponeuroses of abdominal wall at level of renal hila. **A.** The relationships of the muscles, aponeurotic muscle sheaths, and fascia of the abdominal wall are demonstrated in transverse section. The three flat abdominal muscles forming the lateral walls span between complex anterior and posterior aponeurotic formations that ensheath the vertically disposed muscles. The thin anterolateral walls (appearing disproportionately thick here) are distensible. Although flexible, the posterior abdominal wall is weight bearing and so is reinforced by the vertebral column and muscles that act on it; it's not distensible. **B.** Details of the disposition of the aponeurotic and fascial layers of the posterior abdominal wall.

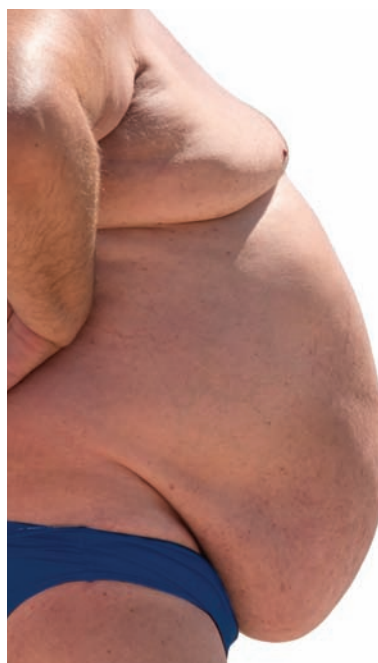
Source: Moore KL, Dalley AF, Agur AMR. *Clinically Oriented Anatomy*. 7th ed. Baltimore, MD: Wolters Kluwer/Lippincott Williams & Wilkins; 2014.



at least one postoperative complication.⁶ Patients with an elevated BMI (BMI greater than 30) had a higher incidence of wound-related complications (44%) than patients with a normal weight (31%; BMI less than 30). Patients who used tobacco had a 41% wound complication rate compared with 20% for patients who were nonsmokers.⁶

Concomitant intra-abdominal procedures and ventral hernia repair performed simultaneously with panniculectomy resulted in a higher incidence of surgical site occurrences (46.5%) when compared with panniculectomy without hernia repair (27.9%).⁹ Surgical site occurrences include all adverse events such as infection, seroma, and delayed wound healing. Despite the occurrence of postoperative complications following simultaneous ventral hernia repair and panniculectomy, studies have demonstrated increased patient satisfaction following combined procedures, with 81% of patients reporting that they were satisfied with their results.¹⁰

Using complex decongestive physical (CDP) therapy with massage, skin care, exercise, and compression



Besides diminishing quality of life, an abdominal pannus can cause maceration, infection, and poor hygiene.

has been effective in reducing complications in patients with an edematous and painful pannus.^{11,12} CDP therapy involves a multicomponent technique designed to reduce the degree of lymphedema and to maintain the health of the skin and supporting structures. This includes skin care, manual lymphatic drainage, compression therapy, and decongestive exercises. Patients receiving preoperative CDP therapy had a significantly reduced rate of postoperative blood transfusions, wound healing disorders, and overall complications.¹¹

Before surgical intervention, patients should be counseled to stop smoking and lose weight. Following surgery, patients can resume their normal medications and follow-up with their healthcare provider as directed. They should avoid prolonged

standing and minimize strenuous activities. Nursing considerations include providing patient education, reinforcing the plan of care, and encouraging adherence.

Surgical incisions

Design patterns for abdominal panniculectomy are typically based on the soft-tissue characteristics of the abdominal wall. Skin and fat redundancy may require excision that's horizontal, vertical, or a combination. Patients with both vertical and horizontal excisions typically have an inverted T incision pattern with the trifurcation point occurring in the suprapubic region. This trifurcation point is occasionally associated with delayed healing due to compromised blood flow. A modification to reduce the incidence of delayed healing at the trifurcation point, the *Mercedes pattern*, incorporates tissue from the suprapubic region.¹³

Other factors dictating the incisions' location include the presence of scars, concomitant procedures, and fat distribution. Most patients with an abdominal hernia have had a prior abdominal incision. The surgeon may incorporate prior incisions into the excision pattern to minimize additional scarring.

Preoperative nursing considerations

Before surgery, a thorough nursing assessment will help ensure that the patient is appropriately prepared for surgery. Obtain a pertinent history to identify health risks, allergies, and current medications that may lead to adverse events intra- and postoperatively. Thoroughly document all allergies including surgical tape, latex, foods, and medications in the medical record. Certain medications, such as aspirin, oral contraceptives, and various nutritional

How is BMI interpreted for adults?

For adults age 20 or older, BMI is interpreted using standard weight status categories. These categories are the same for men and women of all body types and ages.

The standard weight status categories associated with BMI ranges for adults are shown here.

BMI	Weight status
Below 18.5	Underweight
18.5-24.9	Normal or healthy weight
25.0-29.9	Overweight
30.0 and above	Obese

Source: Centers for Disease Control and Prevention. About adult BMI. 2015. https://www.cdc.gov/healthyweight/assessing/bmi/adult_bmi/index.html.

supplements such as fish oils, can lead to increased bleeding or coagulation abnormalities. These are important to share with the surgical team during the presurgical time-out. Whether patients have had prior surgeries and how they recovered is important to know so that the appropriate interventions can be performed to minimize the risk of postoperative complications, including nausea and vomiting.

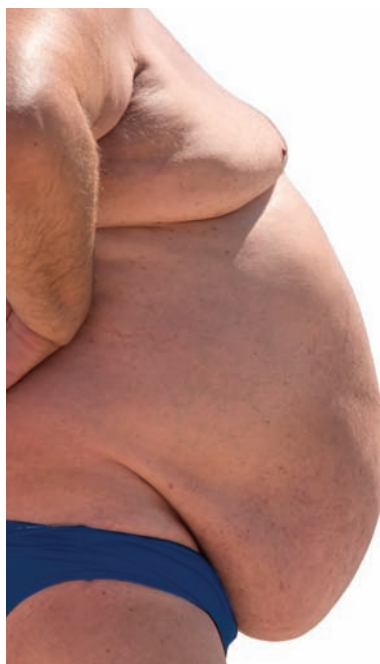Document any cardiopulmonary issues that could interfere with the anesthesia and recovery and that may place the patient at additional risk. Obtain and document vital signs.

Surgical techniques

Preoperatively, the surgeon initiates measures to control and limit blood loss and excessive fluid shifts. One such measure is to place tumescent fluid into the soft tissues of the pannus to cause peripheral vasoconstriction.¹⁴

Panniculectomy is typically performed under general anesthesia and may require from 1 to 2 hours to perform. In general, patients with a large pannus are approached with more caution and limited undermining because excessive undermining may compromise the blood supply and delay healing.¹⁵ *Undermining* is defined as elevating the skin and fat of the abdominal wall off of the anterior rectus sheath.

In this setting, tissue perfusion is optimized by sparing the perforator vessels that traverse the subcutaneous fat en route to the skin. This will improve the circulation at the skin edges and reduce the likelihood of delayed healing. It's important to excise any abnormal or thickened skin. Skin excision is typically performed using a scalpel rather than electrocautery to minimize thermal damage to the edges. Skin closure is performed with minimal tension.¹⁶



Patients undergoing panniculectomy are at risk for VTE, regardless of their BMI.

Closure techniques

Before skin closure, the wounds are copiously irrigated with an antibiotic solution. Closed suction drains are placed in the lateral aspect of the abdominal wall. The closure is completed in layers using absorbable sutures in the superficial fascial layer of the abdomen and the dermis. The cutaneous closure can be performed using staples, absorbable sutures, or nonabsorbable sutures, depending on the perceived risks of infection, delayed healing, and incisional dehiscence.¹⁶

In some cases, the incision isn't closed completely and negative pressure wound therapy (NPWT), also called vacuum-assisted wound closure, is used.^{17,18} This minimizes fluid collection and soft-tissue edema. Once stable, the NPWT can be discontinued and the wound closed by secondary intention.

Intraoperative nursing considerations

Intraoperative nursing care is especially important to ensure that the perioperative phase progresses smoothly and efficiently.

Patients are placed on the OR table and positioned appropriately in the supine position. The arms are usually abducted about 75 degrees and placed on a padded arm board and secured with straps. A urinary catheter is sometimes inserted depending on the expected length of the surgery. Intermittent pneumatic compression (IPC) devices are placed on the lower extremities and turned on before induction of anesthesia.

The nurse, attending surgeon, or resident preps the patient with betadine or chlorhexidine. The circulating nurse is responsible for several factors that include but aren't limited to obtaining the necessary supplies during surgery such as sutures, surgical drains, and dressings.

Postoperative nursing care

Immediately after panniculectomy, monitor patients for signs and symptoms of infection, bleeding, abnormal operative site edema or drainage, hematoma, extreme fluid shifts, and VTE. Ensure that the IPC devices are functioning properly and that vital signs remain stable. Most patients have one or two closed suction drains and wear an abdominal binder. Keep the head of bed elevated at least 30 degrees, unless medically contraindicated, and administer I.V. antibiotics as prescribed; these sometimes continue for the entire hospitalization.¹⁶ The purpose of keeping patients flexed at the waist is to reduce tension on the abdominal incision.

Pain control measures are implemented to ensure patient comfort. Optimal pain management, an important consideration following

panniculectomy, is best achieved by the administration of I.V. or oral opioids as prescribed.^{19,20}

Enhanced recovery after surgery (ERAS) protocols are often implemented to facilitate and provide multimodal pain management, accelerate intestinal recovery, and decrease length of stay. Multimodal pain management strategies include the use of a transverse abdominis plane (TAP) block, liposomal bupivacaine, and oral gabapentin.^{19,20} A TAP block is defined as the injection of a local anesthetic into the plane between the transverse abdominis and the internal oblique muscles of the abdominal wall, where the nerves are located. This triad of medications is effective and can reduce opioid use. ERAS protocols call for nonopioid regimens during the acute postoperative recovery phase to limit the amount of opioids needed to manage the pain.

One untoward effect of opioids is decreased bowel motility, also known as an ileus. Minimizing opioid use can improve intestinal motility and reduce the incidence of opioid-induced constipation. In a recent study of 42 patients after abdominal hernia repair with or without panniculectomy, liposomal bupivacaine was administered immediately at the time of closure via a TAP block consisting of liposomal bupivacaine diluted with 0.9% sodium chloride.²¹ The mean time to first bowel movement decreased from 5 days to 3.4 days and the mean length of hospitalization decreased from 5.8 days to 4.4 days.

Many patients undergoing panniculectomy are at higher risk for VTE, whether they're normal weight, overweight, or obese.^{22,23} Studies have demonstrated that risk is highest in patients having circumferential abdominoplasty or panniculectomy (3.4%) followed by panniculectomy

combined with an intra-abdominal procedure (2.17%).²²

Strategies for VTE prophylaxis include but aren't limited to IPC devices applied in the OR, pre- and postoperative low-dose unfractionated heparin, and low-molecular-weight heparin.²³

The need for blood transfusion after panniculectomy has been studied. In a review of 21,130 patients following massive weight loss and panniculectomy, the incidence of transfusion was 9.3%.²⁴ The need for transfusion is based on clinical parameters such as hypotension associated with a low hematocrit. The likelihood of a postoperative complication increased in patients requiring a transfusion compared with those who didn't (10.1% versus 4.1%).²⁴

Fluid shifts can occur with panniculectomy, especially when it's performed with other abdominal procedures. Third-space fluid shifts may occur because of extensive soft-tissue undermining and excision, resulting in oliguria and electrolyte imbalances. Closely monitor BP and urine output, with an output goal of at least 0.5 mL/kg/hour. In some patients, a diuretic such as furosemide may be indicated. Orthostatic hypotension can be managed with fluid bolus therapy. Monitor levels of serum electrolytes, especially sodium and potassium, which should be maintained within normal ranges.

Postoperative wound complications following panniculectomy may lead to prolonged hospitalization and readmission. These complications include delayed wound healing, incisional dehiscence, surgical site infection, and skin necrosis.^{10,25} In a study of obese patients (BMI greater than 40), two management strategies were compared: leaving the incision open with NPWT versus using primary skin closure.²⁵ For the primary closure group, readmission

was 44% and reoperation was 33%; in contrast, the group managed with an open wound had no wound-related readmissions or reoperative debridements.

Nursing's impact

Nurses' preoperative roles now include correction of nutritional deficiencies, optimization of medical comorbidities, and patient education. Postoperative care encompasses the implementation of ERAS protocols, wound care, VTE prophylaxis, and CDP therapy. Providing optimal nursing care can make the difference in patient outcomes and patients' satisfaction after panniculectomy. ■

REFERENCES

1. Schauer PR, Bhatt DL, Kirwan JP, et al. Bariatric surgery versus intensive medical therapy for diabetes—3-year outcomes. *N Engl J Med*. 2014; 370(21):2002-2013.
2. Pestana IA, Campbell D, Fearmonti RM, Bond JE, Erdmann D. "Supersize" panniculectomy: indications, technique, and results. *Ann Plast Surg*. 2014;73(4):416-421.
3. Gray JE, Mizell JS. Anatomy of the abdominal wall. 2015. www.UpToDate.com.
4. Gonzalez-Ulloa M. Abdominal wall disfigurement. *Ann Plast Surg*. 1980;4(5):357-369.
5. Cheesborough JE, Dumanian GA. Simultaneous prosthetic mesh abdominal wall reconstruction with abdominoplasty for ventral hernia and severe rectus diastasis repairs. *Plast Reconstr Surg*. 2015; 135(1):268-276.
6. Zannis J, Wood BC, Griffin LP, Knipper E, Marks MW, David LR. Outcome study of the surgical management of panniculitis. *Ann Plast Surg*. 2012; 68(2):194-197.
7. Almutairi K, Gusenoff JA, Rubin JP. Body contouring. *Plast Reconstr Surg*. 2016;137(3): 586e-602e.
8. Naghshineh N, O'Brien Coon D, McTigue K, Courcoulas AP, Fernstrom M, Rubin JP. Nutritional assessment of bariatric surgery patients presenting for plastic surgery: a prospective analysis. *Plast Reconstr Surg*. 2010;126(2):602-610.
9. Warren JA, Epps M, Debrux C, et al. Surgical site occurrences of simultaneous panniculectomy and incisional hernia repair. *Am Surg*. 2015;81(8): 764-769.
10. Cooper JM, Paige KT, Beshlian KM, Downey DL, Thirlby RC. Abdominal panniculectomies: high patient satisfaction despite significant complication rates. *Ann Plast Surg*. 2008;61(2): 188-196.
11. Koulaxouzidis G, Goerke SM, Eisenhardt SU, et al. An integrated therapy concept for reduction of postoperative complications after resection of a panniculus morbidus. *Obes Surg*. 2012;22(4): 549-554.

12. Apich G. [Conservative lymphedema therapy—lymphological rehabilitation treatment.] [Article in German.] *Wien Med Wochenschr.* 2013;163(7-8):169-176.
13. Butler CE, Reis SM. Mercedes panniculectomy with simultaneous component separation ventral hernia repair. *Plast Reconstr Surg.* 2010;125(3):94e-98e.
14. Klein JA, Jeske DR. Estimated maximal safe dosages of tumescent lidocaine. *Anesth Analg.* 2016;122(5):1350-1359.
15. Petty P, Manson PN, Black R, Romano JJ, Sitzman J, Vogel J. Panniculus morbidus. *Ann Plast Surg.* 1992;28(5):442-452.
16. Heger P, Pianka F, Diener MK, Mihaljevic AL. [Current standards of abdominal wall closure techniques: conventional suture techniques.] [Article in German.] *Chirurg.* 2016;87(9):737-743.
17. Cirocchi R, Birindelli A, Biffl WL, et al. What is the effectiveness of the negative pressure wound therapy (NPWT) in patients treated with open abdomen technique? A systematic review and meta-analysis. *J Trauma Acute Care Surg.* 2016;81(3):575-584.
18. Kugler NW, Carver TW, Paul JS. Negative pressure therapy is effective in abdominal incision closure. *J Surg Res.* 2016;203(2):491-494.
19. Vyas KS, Rajendran S, Morrison SD, et al. Systematic review of liposomal bupivacaine (Exparel) for postoperative analgesia. *Plast Reconstr Surg.* 2016;138(4):748e-756e.
20. Morales R Jr, Mentz H 3rd, Newall G, Patronella C, Masters O 3rd. Use of abdominal field block injections with liposomal bupivacaine to control postoperative pain after abdominoplasty. *Aesthet Surg J.* 2013;33(8):1148-1153.
21. Fayeziadeh M, Petro CC, Rosen MJ, Novitsky YW. Enhanced recovery after surgery pathway for abdominal wall reconstruction: pilot study and preliminary outcomes. *Plast Reconstr Surg.* 2014;134(4 suppl 2):151S-159S.
22. Hatef DA, Trussler AP, Kenkel JM. Procedural risk for venous thromboembolism in abdominal contouring surgery: a systematic review of the literature. *Plast Reconstr Surg.* 2010;125(1):352-362.
23. Reish RG, Damjanovic B, Colwell AS. Deep venous thrombosis prophylaxis in body contouring: 105 consecutive patients. *Ann Plast Surg.* 2012;69(4):412-414.
24. Masoomi H, Rimler J, Wirth GA, Lee C, Paydar KZ, Evans GR. Frequency and risk factors of blood transfusion in abdominoplasty in post-bariatric surgery patients: data from the nationwide inpatient sample. *Plast Reconstr Surg.* 2015;135(5):861e-868e.
25. Brown M, Adenuga P, Soltanian H. Massive panniculectomy in the super obese and super-obese: retrospective comparison of primary closure versus partial open wound management. *Plast Reconstr Surg.* 2014;133(1):32-39.

Maurice Y. Nahabedian is professor and vice chairman of the department of plastic surgery at Georgetown University in Washington, D.C. Anissa G. Nahabedian is an RN at Sibley Hospital in Washington, D.C.

Dr. Nahabedian is a speaker and consultant for Allergan Corporation. The authors and planners have disclosed no other potential conflicts of interest, financial or otherwise.

DOI-10.1097/01.NURSE.0000524753.74764.5e

> For more than 105 additional continuing education articles related to surgery topics, go to NursingCenter.com/CE. <



Earn CE credit online:
Go to www.nursingcenter.com/CE/nursing and receive a certificate within minutes.

INSTRUCTIONS

Panniculectomy: Perioperative nursing considerations

TEST INSTRUCTIONS

- To take the test online, go to our secure website at www.nursingcenter.com/ce/nursing.
- On the print form, record your answers in the test answer section of the CE enrollment form on page 39. Each question has only one correct answer. You may make copies of these forms.
- Complete the registration information and course evaluation. Mail the completed form and registration fee of \$12.95 to: **Lippincott Professional Development**, 74 Brick Blvd., Bldg. 4, Suite 206A, Brick, NJ 08723. We will mail your certificate in 4 to 6 weeks. For faster service, include a fax number and we will fax your certificate within 2 business days of receiving your enrollment form.
- You will receive your CE certificate of earned contact hours and an answer key to review your results.
- Registration deadline is October 31, 2019.

DISCOUNTS and CUSTOMER SERVICE

- Send two or more tests in any nursing journal published by Lippincott Williams & Wilkins together by mail, and deduct \$0.95 from the price of each test.
- We also offer CE accounts for hospitals and other healthcare facilities on nursingcenter.com. Call **1-800-787-8985** for details.

PROVIDER ACCREDITATION

Lippincott Professional Development will award 1.0 contact hour for this continuing nursing education activity.

Lippincott Professional Development is accredited as a provider of continuing nursing education by the American Nurses Credentialing Center's Commission on Accreditation.

Lippincott Professional Development is also an approved provider of continuing nursing education by the District of Columbia, Georgia, and Florida CE Broker #50-1223. This activity is also provider approved by the California Board of Registered Nursing, Provider Number CEP 11749 for 1.0 contact hour.